

The Impact of Khat (*Catha edulis*) on Hemodynamics of the Common Carotid Arteries in Regular Khat Chewers: A Case-control Study Using Doppler Ultrasound

Moawia Gameraddin^{1*}, Bushra A. Abdalmalik², Mohamed Ibrahim³

¹Department of Diagnostic Radiologic Technology, Faculty of Applied Medical Sciences, Taibah University, Medina, Saudi Arabia, ²Department of Diagnostic Radiology Sciences, Faculty of Applied Medical Sciences, Hail University, Hail, Saudi Arabia, ³Faculty of Medicine, University of Hargeisa, Hargeisa, Somaliland

Abstract

Background: To evaluate the effect of chewing khat on the hemodynamics of the common carotid arteries (CCAs) using Doppler ultrasound imaging. **Methods:** This is a cross-sectional case-control study. Fifty volunteers who were chronic regular khat chewers were selected and compared with healthy nonkhat chewers. They were examined using Doppler imaging with a 7–10 MHz linear transducer. The resistivity index (RI), pulsatility index (PI), peak systolic velocity (PSV), and end-diastolic velocity of the CCAs were determined according to the standard protocol of carotid Doppler ultrasound. **Results:** The RI and PI of the right and left CCAs were significantly higher in khat chewers compared to controls ($P < 0.001$). The PSV of the right and left CCAs was considerably higher in khat chewers compared to controls ($P < 0.001$ and 0.04, respectively). **Conclusion:** The Doppler values of blood flow velocity, resistivity, and pulsatility were significantly higher in chronic regular khat chewers compared to nonkhat chewers. Khat is a significant contributory factor for increasing the hemodynamics of the CCAs.

Keywords: Cardiovascular, carotid, chewers, hemodynamics, khat

INTRODUCTION

Catha edulis (commonly known as khat or qat) is a plant that produces a psychoactive substance that contains cathine and cathinone and has a similar structure and action to amphetamine.^[1] Khat grows in equatorial climates, such as Africa and the Arabian Peninsula.^[2,3] *C. edulis* belongs to the *Celastraceae* family.^[4] Cathine and cathinone are responsible for increasing heart rate (HR) and blood pressure (BP).^[5]

Regular khat consumption has been associated with elevated HR and BP. Khat chewers reportedly had a higher risk of various cardiovascular diseases, such as cardiogenic shock, recurrent myocardial ischemia, and ventricular arrhythmia.^[6] Khat chewing is also associated with stroke and hypertension.^[6,7] Therefore, studying the hemodynamics of the common carotid arteries (CCAs) may contribute to predicting cerebrovascular abnormalities.

Only a few attempts have been made to explain the relationship between khat and cardiovascular disease. Studying the influence of khat on hemodynamics is very important, since the elevation of HR and BP may lead to peripheral vascular events. Studying the effects of khat on carotid hemodynamics may be helpful in detecting cerebrovascular problems of the brain. Currently, few studies in literature demonstrate the impact of khat on hemodynamics of the CCAs. The ultimate aim of this study is to evaluate the impact of khat on the hemodynamics of the CCAs in regular khat chewers.

MATERIALS AND METHODS

This was a prospective, case-control study designed to investigate the impact of khat (*C. edulis*) on the hemodynamics

Address for correspondence: Dr. Moawia Gameraddin,
Department of Diagnostic Radiologic Technology, College of Applied Medical
Sciences, Taibah University, Medina, KSA.
E-mail: gameraddinm@gmail.com

Received: 09-02-2020 Revised: 07-06-2020 Accepted: 22-06-2020 Available Online: 20-03-2021

Access this article online

Quick Response Code:



Website:
www.jmuonline.org

DOI:
10.4103/JMU.JMU_22_20

This is an open access journal, and articles are distributed under the terms of the Creative Commons Attribution-NonCommercial-ShareAlike 4.0 License, which allows others to remix, tweak, and build upon the work non-commercially, as long as appropriate credit is given and the new creations are licensed under the identical terms.

For reprints contact: WKHLRPMedknow_reprints@wolterskluwer.com

How to cite this article: Gameraddin MB, Abdalmalik BA, Ibrahim M. The impact of khat (*Catha edulis*) on hemodynamics of the common carotid arteries in regular khat chewers: A case-control study using Doppler ultrasound. J Med Ultrasound 2021;29:46-9.

of the CCAs using duplex ultrasound. The study was performed at Kaah Community Hospital in Hargeisa, Somaliland, between September 2017 and December 2017. The study was approved by the Ethical Committee Board of the National Ribat University (IRB approval no. RNU112017), and informed consent was obtained from all participants. The study compared 50 volunteers (48 males and 2 females) who were regularly chewing khat with 50 asymptomatic volunteers (47 males and 3 females) who did not chew khat as the control group. The khat chewers consumed amount of 100–300 g of qat fresh leaves which were regularly chewed per day. The sample size was selected using a simple and convenient systematic sampling method. A designed data collection sheet was used to collect demographic and clinical data, such as clinical history, the status of chewing khat, and the duration of chewing khat. Participants with diabetes mellitus, hypertension, renal and cardiac diseases, and stenosis of the carotid arteries were excluded since these abnormalities could influence the blood flow velocities of the carotid arteries.

The Doppler sonographic procedure

The Doppler investigations were performed using DC-N3 ultrasound equipment (Mindray, China) with a linear high-frequency transducer (7–10 MHz). The B-mode settings were adjusted to optimize the image quality before applying the Doppler imaging. Both right and left CCAs were examined using duplex ultrasound.

The participants were investigated in the supine position with the head extended upward and turned away from the side being examined. Doppler parameters were adjusted to optimize good signal intensity. Pulsed wave Doppler measurements were performed using a sample volume that covered the one-third width of the vessel lumen. Flow velocities were recorded once the signal was stable for at least 5 s. The Doppler frequencies were performed by adjusting the angle of the Doppler beam at the course of the artery. The Doppler wave measurements were analyzed and stored using the hard drive of the ultrasound equipment and computer. The Doppler flow velocities were measured in each CCA as follows: (1) peak systolic velocity (PSV) and (2) maximum end-diastolic velocity (EDV). The resistivity index (RI) and pulsatility index (PI) were automatically calculated by the ultrasound machine.

Statistical analysis

The statistical analysis was performed using the Statistical Package for the Social Sciences version 16.0 (IBM, Cary, North Carolina, USA). The independent *t*-test was used to compare the Doppler indices of the CCAs between the khat chewers and the controls. Qualitative data were described by means and frequencies. $P < 0.05$ was considered statistically significant.

RESULTS

Fifty regular khat chewers were investigated in this study. There were 48 (96%) males and only 2 (4%) females. Table 1 summarizes the demographic characteristics of the khat users and the controls. The mean age of the khat users was

35.9 ± 9 years, whereas the mean age of the controls was 30.86 ± 7 years old. The majority of the khat chewers were in the 31–40-year-old age group. The mean duration of khat chewing was 15.68 ± 8 years, as calculated from the duration groups.

Table 2 summarizes the comparison of CCA hemodynamics in regular khat chewers and controls. The RI and PI of the right and left CCAs were significantly higher in khat chewers compared to controls ($P < 0.001$). The PSV was significantly higher in the right and left CCAs (89.31 ± 10.66 vs. 76.47 ± 9.87 cm/s and 84.78 ± 12.032 vs. 80.47 ± 8.90 cm/s; $P < 0.001$ and 0.04 , respectively). The EDV of the right and left CCAs was also higher in cases compared to controls (18.13 ± 2.24 vs. 15.58 ± 2.58 cm/s and 17.51 ± 1.70 vs. 16.99 ± 2.60 cm/s, respectively). Overall, the Doppler values of the carotid blood velocities were significantly higher in the khat chewers compared to the nonkhat chewers.

Age and gender had no significant correlation with Doppler parameters of CCAs in chronic regular khat chewers ($P < 0.05$) as shown in Table 3. The correlations were very weak. The

Table 1: Demographic characteristics of the study population

	Khat chewers (<i>n</i> =50)	Controls (<i>n</i> =50)	<i>P</i>
Men, <i>n</i> (%)	48 (96)	47 (94)	0.65
Mean age (years), <i>n</i> (%)	34.58±8.4	32.8±10.6	0.36
<20	5 (10)	10 (20)	
21-30	11 (22)	18 (36)	.02
31-40	16 (32)	13 (26)	
41-50	10 (20)	9 (18)	
51-60	8 (16)		
Mean duration of khat chewing (years), <i>n</i> (%)	15.68 ± 8 years		
<5	7 (14)		
5-15	21 (28)		
16-25	17 (34)		
26-35	5 (10)		

Table 2: Comparison of Doppler indices of the common carotid arteries in khat chewers and controls

	Khat chewers	Controls	<i>P</i>
Right CCA			
PSV (cm/s)	89.31±10.66	76.47±9.87	<0.001
EDV (cm/s)	18.13±2.24	15.58±2.58	<0.001
RI	0.82±0.04	0.79±0.03	<0.001
PI	2.28±0.37	2.01±0.32	<0.001
Left CCA			
PSV (cm/s)	84.78±12.032	80.47±8.90	0.04
EDV (cm/s)	17.51±1.70	16.99±2.60	0.24
RI	0.80±0.04	0.77±0.05	<0.001
PI	2.39±0.43	2.33±0.35	0.42

CCA: Common carotid artery, RI: Resistivity index, PI: Pulsatility index, PSV: Peak systolic velocity, EDV: End-diastolic velocity

insignificant and weak correlation excluded the impact of age and gender on hemodynamics of the CCAs in this sample study.

Figure 1 summarizes the comparison of systolic and diastolic BPs between khat chewers and controls. They were significantly higher in the khat chewers than the controls ($P < 0.05$). Figure 2 summarizes the comparison of HR between khat chewers and controls. The HR was significantly increased in khat chewers than controls ($P < 0.05$).

DISCUSSION

Considering the growing prevalence of khat chewing worldwide, the implications are essential since abnormal elevation in HR and BP are considered key risk factors for the pathogenesis of cardiovascular and cerebrovascular lesions.^[8,9] Besides the rise in BP and HR that have been well demonstrated in previous studies, the current study revealed that the Doppler indices of the CCAs were changed in regular khat chewers. The insignificant and weak correlation which we found in this study excluded the impact of age and gender on hemodynamics of the CCAs.

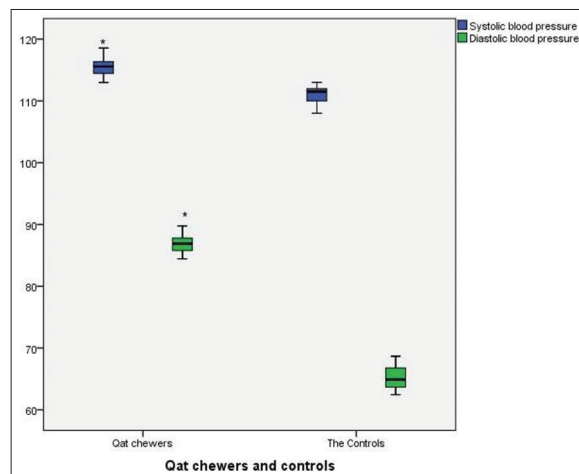


Figure 1: Comparison of systolic and diastolic blood pressure between qat chewers and controls. *Significance at the 0.05 level (two-tailed)

In the current study, it was found that the Doppler indices RI and PI were significantly elevated in khat chewers compared to controls ($P < 0.001$). There is only one study in the literature demonstrating the effect of khat on the hemodynamics of the CCAs; it revealed the immediate influence of chewing khat on RI and PI. Ibrahim *et al.* studied the immediate effect of khat on the hemodynamics of the CCAs using Doppler imaging. They found that the RI and PI were significantly lower after chewing khat.^[10] They studied the influence for 2 h before and after chewing khat. In contrast, the RI and PI in the current study increased significantly due to the long-term use of khat for several years. There are no existing studies to compare these findings with. In previous studies, khat was reported to affect the coronary arteries and caused marked vasoconstriction.^[11] The same effect may happen in the CCAs and cause elevation of the CCA Doppler indices. This effect might be attributed to the peripheral vasoconstrictor effect of cathinone,^[6,4,7,12] which may be persistent for a long time in regular khat chewers.

The current study demonstrated that the PSV and EDV of the CCAs were significantly elevated in the khat chewers compared to the controls. Consistent with this finding, Ibrahim *et al.*

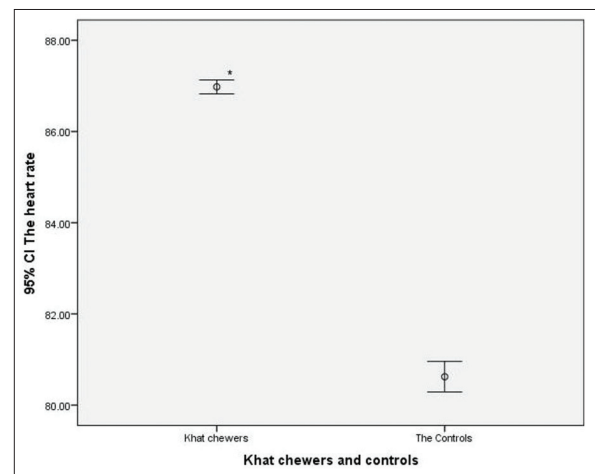


Figure 2: Comparison of heart rate between qat chewers and controls. *Significance at the 0.05 level (two-tailed)

Table 3: Correlation of gender and age with Doppler parameters in regular khat chewers

	Gender		Age	
	Correlation coefficient (r)	P	Correlation coefficient (r)	P
Right CCA				
PSV (cm/s)	-0.022	0.825	0.035	0.729
EDV (cm/s)	-0.093	0.357	-0.096	0.340
RI	-0.052	0.605	0.060	0.550
PI	-0.024	0.812	-0.024	0.809
Left CCA				
PSV (cm/s)	-0.184	0.067	-0.179	0.075
EDV (cm/s)	0.051	0.614	-0.108	0.286
RI	0.063	0.536	0.014	0.894
PI	0.120	0.235	0.064	0.530

CCA: Common carotid artery, RI: Resistivity index, PI: Pulsatility index, PSV: Peak systolic velocity, EDV: End-diastolic velocity

revealed a significant effect of khat on the blood hemodynamics of the CCAs. They reported that the PSV and EDV increased after chewing khat.^[10] The elevation of blood flow velocity might be attributed to increased HR and BP as a consequence of chewing khat. Abnormal carotid flow velocities and pulsatility may be associated with cardiovascular events.^[13,14]

The difference and mechanism between immediate and long-term effect of khat is governed by the duration of khat chewing. Long duration of khat chewing accumulates considerable amount of cathine and cathinone which are responsible for alterations flow velocities and resistances. It was reported that a duration of 4 h causes increased BP and HR with decreased RI and PI.^[10] Another study reported that the long term of khat chewing was significantly associated with increased systolic BP and diastolic BP.^[8] Consequently, the increased BP would elevate the Doppler parameters. Unfortunately, no previous studies have demonstrated the impact of khat on blood flow velocity in the CCAs.

In general, there is not much research in the literature concerning the impact of khat on the hemodynamics of blood vessels. Considering the effect of khat on the coronary arteries, as stated in the literature, we suggest that the same events might occur in the carotid arteries. The implications of khat on the heart may produce a considerable effect on the hemodynamics of the peripheral arteries, such as the CCAs.

This study faced major limitations since it was a single-center study. Second, the majority of khat chewers were also smokers. We found difficulty in excluding smokers. Therefore, this affected the sample size, which was not large enough. Furthermore, no previous studies have demonstrated the effect of khat on the hemodynamics of the carotid vessels. To assess the effect of chronic khat chewing on hemodynamics of CCAs, further studies with larger sample size need to be undertaken.

CONCLUSION

The values of the blood flow velocity parameters of the carotid arteries were significantly elevated in regular khat chewers. Understanding the impact of khat on carotid artery hemodynamics is essential in the prediction of cerebrovascular abnormalities.

Acknowledgment

We wish to thank the staff in Hargeisa Hospital Somaliland, Radiology department for performing the Doppler

investigations, and their great assistance to achieve this work.

Financial support and sponsorship

Nil.

Conflicts of interest

There are no conflicts of interest.

REFERENCES

1. Sallam MA, Sheikh KA, Baxendale R, Azam MN, El-Setouhy M. The physiological and perceptual effects of plant extracts (*Catha edulis* Forsk) during sustained exercise. *Subst Abuse Treat Prev Policy* 2016;11:18.
2. El-Zaemey S, Schüz J, Leon ME. Qat chewing and risk of potentially malignant and malignant oral disorders: A systematic review. *Int J Occup Environ Med* 2015;6:129-43.
3. Ali WM, Zubaid M, Al-Motarreb A, Singh R, Al-Shereiqa SZ, Shehab A, *et al.* Association of Khat chewing with increased risk of stroke and death in patients presenting with acute coronary syndrome. *Mayo Clin Proc* 2010;85:974-80.
4. Al-Motarreb A, Baker K, Broadley KJ. Khat: Pharmacological and medical aspects and its social use in Yemen. *Phytother Res* 2002;16:403-13.
5. Birhane BW. The effect of Khat (*Catha edulis*) chewing on blood pressure among male adult chewers, Bahir Dar, North West Ethiopia. *Sci J Public Health* 2014;2:461.
6. Mega TA, Dabe NE. Khat (*Catha edulis*) as a risk factor for cardiovascular disorders: Systematic review and meta-analysis. *Open Cardiovasc Med J* 2017;11:146-55.
7. Geta TG, Woldeamanuel GG, Hailemariam BZ, Bedada DT. Association of chronic Khat chewing with blood pressure and predictors of hypertension among adults in Gurage Zone, Southern Ethiopia: A comparative study. *Integr Blood Press Control* 2019;12:33-42.
8. Thune JJ, Signorovitch J, Kober L, Velazquez EJ, McMurray JJ, Califf RM, *et al.* Effect of antecedent hypertension and follow-up blood pressure on outcomes after high-risk myocardial infarction. *Hypertension* 2008;51:48-54.
9. Singh B. Increased heart rate as a risk factor for cardiovascular disease. *Eur Heart J* 2003;5 Suppl G: G3-9.
10. Ibrahim M, Malik AHB, Gameraddin M. Doppler assessment of the effect of chewing qat on hemodynamics of the common carotid arteries. *J Med Sci* 2017;17:95-101.
11. El-Menyar A, Mekkodathil A, Al-Thani H, Al-Motarreb A. Khat use: History and heart failure. *Oman Med J* 2015;30:77-82.
12. Chong XZ, Alshagga M, Saed KA, Kassim S. Impact of khat (*Catha edulis*) chewing/use on heart rate and blood: A critical review. *Malaysian J Public Health Med* 2017;17:76-85.
13. Alshagga MA, Alshawsh MA, Seyedan A, Alsalahi A, Pan Y, Mohankumar SK, *et al.* Khat (*Catha edulis*) and obesity: A scoping review of animal and human studies. *Ann Nutr Metab* 2016;69:200-11.
14. Chuang SY, Cheng HM, Bai CH, Yeh WT, Chen JR, Pan WH. Blood pressure, carotid flow pulsatility, and the risk of stroke: A community-based study. *Stroke* 2016;47:2262-8.